



International Journal of Homoeopathic Sciences

E-ISSN: 2616-4493

P-ISSN: 2616-4485

www.homoeopathicjournal.com

IJHS 2023; 7(3): 373-375

Received: 09-06-2023

Accepted: 17-07-2023

Greeshma SS

PG Scholar, Department of
Materia Medica, Sarada
Krishna Homoeopathic
Medical College, (Affiliated To
The Tamil Nadu Dr. M.G.R.
Medical University, Chennai),
Kulasekharam, Kanyakumari,
Tamil Nadu, India

CR Krishna Kumari Amma

PG and Ph.D. Guide,
Department of Materia
Medica, Sarada Krishna
Homoeopathic Medical
College, (Affiliated to The
Tamil Nadu Dr. M. G. R.
Medical University, Chennai),
Kulasekharam, Kanyakumari,
Tamil Nadu, India

Raveena R

Intern, Sarada Krishna
Homoeopathic Medical
College, (Affiliated to The
Tamil Nadu Dr. M. G. R.
Medical University, Chennai),
Kulasekharam, Kanyakumari,
Tamil Nadu, India

Corresponding Author:

Greeshma SS

PG Scholar, Department of
Materia Medica, Sarada
Krishna Homoeopathic
Medical College, (Affiliated To
The Tamil Nadu Dr. M.G.R.
Medical University, Chennai),
Kulasekharam, Kanyakumari,
Tamil Nadu, India

Efficacy of Natrum muriaticum 1m potency in the treatment of lichen planus: A case report

Greeshma SS, CR Krishna Kumari Amma and Raveena R

DOI: <https://doi.org/10.33545/26164485.2023.v7.i3f.938>

Abstract

Lichen planus is an inflammatory condition of the skin and mucous membranes. It is occurring when the immune system mistakenly attacks cells of the skin or mucous membranes. The prevalence of Lichen planus in the total population is unknown. The frequency is estimated at between 0.5 and 1.0%. LP affects patients of all ages, but up to 95% of all cases occur in adults, with most patients presenting between the third and sixth decades of life. In this case a fifty-five-year-old lady came with the complaint of blackish eruption in both upper and lower extremities. Along with severe itching for last 2 years. Her complaints were getting aggravated from night, warmth of bed, and ameliorated by cold water bath and rubbing. The medicine given was Natrum muriaticum in 0/1 potency, 1 dose, then followed by saccharum lactum. Within a period of 1 month patient shows marked improvement. This case report shows the role of fifty millesimal potency in the treatment of lichen planus, without any local application.

Keywords: Homoeopathy, Individualization, lichen planus, natrum muriaticum

Introduction

An inflammatory condition of the skin and mucous membranes with no known cause is lichen planus (LP). Most frequently found on the wrists, lower back, and ankles, it appears as irritable, violaceous papules and plaques. Above the lesions there is a network of white lines that resembles a lattice known as Wickham striae. These lines are seen on the buccal mucosa, where erosions may also be present. Drug-induced lichen planus, also known as lichenoid drug eruption, is frequently photographed but can sometimes be confused with idiopathic LP. Within 1 to 2 years of initial presentation, most of the patients with cutaneous lesions spontaneously clear. However, recurrences are frequent, and persistent skin hyperpigmentation frequently follows. Comparatively, oral LP is a chronic condition that may or may not go away. Drug-induced LP gradually goes away after the harmful drug is ceased [1].

According to current theories, individuals with a genetic predisposition to lichen planus (LP) develop the condition as part of a T cell-mediated autoimmune reaction against basal epithelial keratinocytes. Drug-induced LP, also known as lichenoid drug eruption, can be difficult to distinguish from non-drug-induced LP or have a more eczematous pattern. Drugs, particularly beta-blockers, nonsteroidal anti-inflammatory drugs [NSAIDs], angiotensin-converting enzyme inhibitors, sulfonylureas, gold, antimalarial drugs, penicillamine, and thiazides, can cause LP. Primary biliary cholangitis, formerly known as primary biliary cirrhosis, and hepatitis (including hepatitis B infection, hepatitis B vaccination, and, particularly, hepatitis C-induced liver insufficiency) have been linked [2].

Symptoms of lichen planus vary depending on the part of the body affected. Nail disease usually affects several nails. Symptoms are Purple, shiny, flat bumps, often on the inner forearms, wrists or ankles. Lines of rash where the skin has been scratched. Lacy white patches on the tongue or inside of the cheeks. Itchiness. Painful sores in the mouth or genitals. Rarely, hair loss. Nail scarring or loss. Dark lines from the tip of the nail to the base [3].

Hypertrophic LP is most frequently found on the lower limbs, particularly those near the ankles, and typically manifests as scaly, hypertrophic nodules during the course of a sub-acute attack. The disease's progression is slowed down by the development of hypertrophic lesions, and after they have cleared, a pigmented area, a scar, and frequently some degree of atrophy is still present. It is intensely pruritic in nature [4].

Case summary

A fifty-five-year-old lady came with the complaint of blackish eruption in both upper and lower extremities. The Patient was apparently well before 2 years. She suddenly started with the complaint of multiple, flat topped, blackish papules eruption on the left leg which gradually progressed to both legs and arms. The eruptions are dry, blackish in colour and spread all over the both upper and lower extremities. She has itching over the eruption which is aggravated by night, warmth of bed, and ameliorated by cold water bath and rubbing. She has burning sensation after itching. History of past illness led us to know that she has suffered from chicken pox at age of 15 years and got relieved from allopathic treatment. Among the generals, Stool is hard, constipated, once in 2 days with unfinished sensation. She is easily angered for silly things. Very Forgetful, she can't remember the things were she kept. She is hot patient with desire for pickles. She Likes cold

weather, desire fanning, open air and aversion covering. There is no history of, redness, tenderness, swelling and discharge from the eruption. She is Introvert. She feels long lasting grief from sudden death of her mother. She has suppressed emotions, want to be alone when she is sad.

Analysis of the Case

With the help of characteristic mental & physical symptoms, we formed the totality of symptoms and individualize the patient.

Table 1: Totality of symptoms

Long continued grief
Anger easily
Forgetful
Desire salty food
Eruption over both upper and lower extremity
Itching

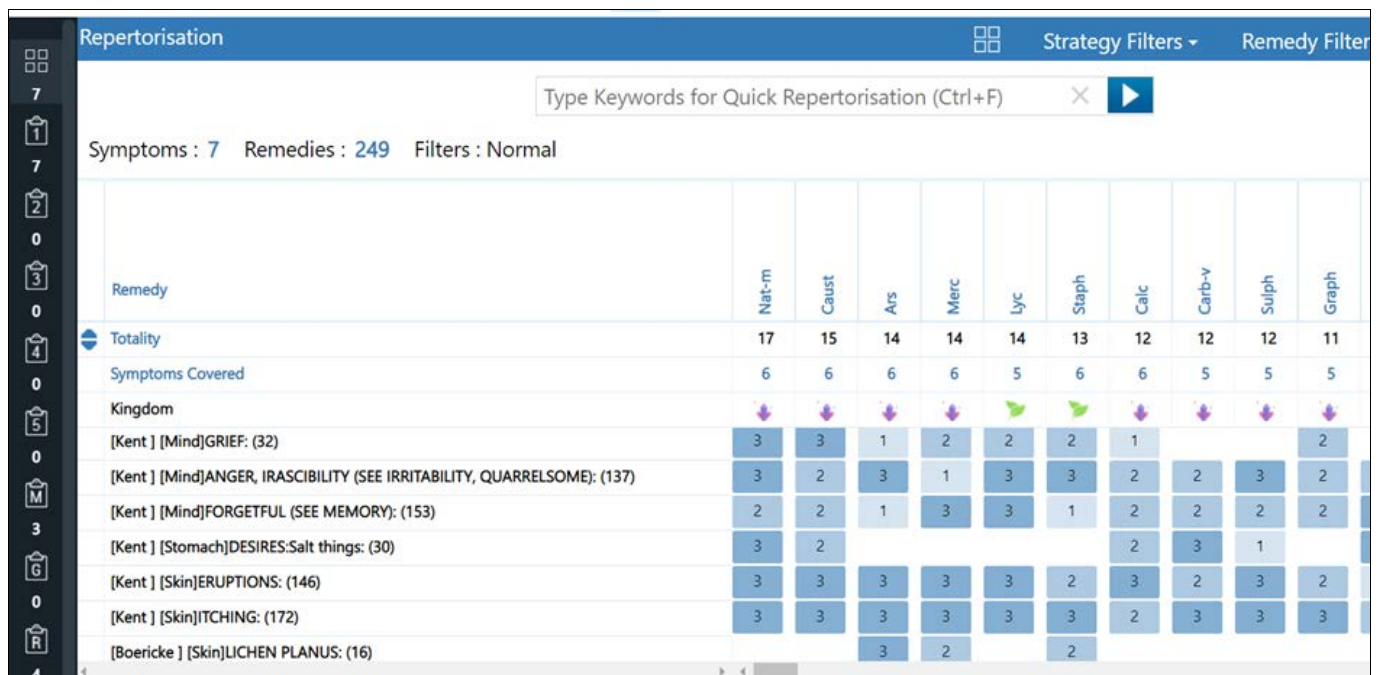


Chart 1: Repertorial chart

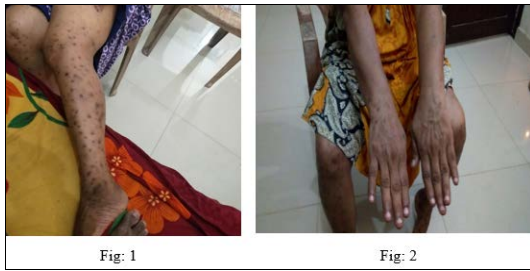Repertorial Result
 Natrum muriaticum: 17/6
 Causticum: 15/6
 Ars alb:14/6

Merc sol: 14/6
 Lycopodium: 14/5
 Staphysagria: 13/6

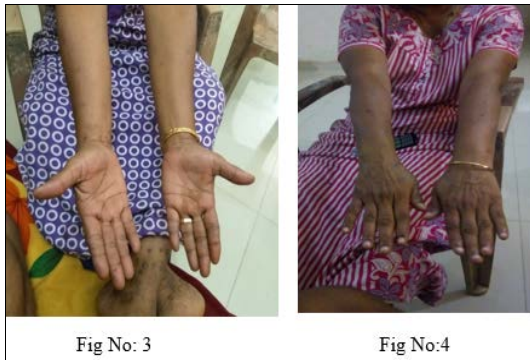Timeline of treatment

Date	Present complaints	Medicine prescription
First Visit 7.05.2022	Complaints of multiple, flat topped, blackish papules eruption on the left leg. The eruptions are dry, blackish in colour and spread all over the both upper and lower extremities. Itching ⁺⁺ <night < warmth of bed >cold water bath > rubbing	Natrum Muriaticum 0/1, 1 dose Placebo for 14 days
Second visit 21/5/22	Flat topped, blackish papules in upper extremity is better than before. Eruption still persist on lower extremity. Itching get aggravated.	Placebo for 1 month.
Third visit 25/6/22	Eruptions better in both upper and lower extremity. Itching feels better Generals: Good	Placebo for 1 month.

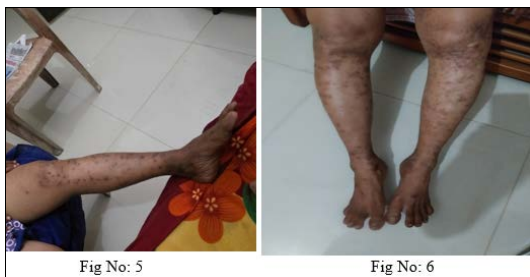Clinical images and progress



First visit: 7/5/22



Second visit: 21/5/22



Third visit: 25/6/22

Discussion

Lichen planus is a chronic inflammatory disease of the skin and mucus membranes. It has a negative effect on the patient's emotional and physical well-being. Within one or two years, this condition spontaneously resolves [5]. Therefore, the main goal of treatment is to shorten the duration of symptoms and their onset. This hypertrophic LP case illustrates the role of homoeopathic medicine in a fifty millesimal potency. When homoeopathic medicine is prescribed based on the totality of symptoms, both the distressing symptoms reduced within a short period. Medicinal aggravations which are the common features of centesimal scale, does not exist in fifty millesimal scale [6]. Medicines of highest powers and mildest action are the result of this new scale of potentization [7]. A very careful history of patient, extensive clinical examination, and individualization of the case on the basis of homoeopathic philosophy help us select the *Natrum muriaticum* 0/1 and followed by placebo.

One previous study shows that found that female gender is more commonly affected with lichen planus than males.¹⁰ There are many case reports showing the effectiveness of similar remedy in lichen planus cases [8]. Homoeopathic treatment claims it's because of individualistic approach. Here in this case, with complaints of multiple, flat topped, blackish papules eruption on the both upper and lower

extremity for last 2 year. It has been treated successfully with ultra-diluted homoeopathic medicines. Homeopaths believe that individual personality traits lead to unique predispositions to disease, which is why homoeopathic treatments are tailored to the patient. Since the goal of a homoeopathic consultation is to identify personality traits in the patient that can be matched by the profile of the homoeopathic medicine, it is often similar to a psychological consultation [9].

Conclusion

The case report shows a case of Lichen planus treated with fifty millesimal potency on the basis of totality of symptoms. It shows positive effect of treatment, individualized homoeopathic medicine in managing the case of Lichen Planus. It aids as a valuable study in such cases although conclusions should be made from further systematic studies.

Conflict of Interest

Not available

Financial Support

Not available

Reference

- <https://www.ncbi.nlm.nih.gov/books/NBK526126/>
- <https://www.msdmanuals.com/en-in/professional/dermatologic-disorders/psoriasis-and-scaling-diseases/lichenplanus>
- <https://www.mayoclinic.org/diseases-conditions/lichen-planus/symptoms-causes/syc-20351378>
- <https://www.researchgate.net/publication/283298738>
- <https://www.ncbi.nlm.nih.gov/books/NBK526126/#article-24254.s8>
- 50 millesimal potency in theory and practice. Third revised and enlarged edition Dr Harimohan Choudhury. B Jain Publishers (P) Ltd
- Organon of medicine 5th and 6th edition Dr Samuel Hahnemann.
- Sasmal S, Mallick K, Mallick P. Lichen Planus Treated By individualized Homoeopathic Medicine-A Case Report. International Journal of AYUSH Case Reports. 2022 Mar 17;6(1):82-7.
- Nwabudike LC, Miulescu M, Tatu AL. Case series of an alternative therapy for generalised lichen planus: Four case studies. Experimental and therapeutic medicine. 2019 Aug 1;18(2):943-8.
- Rampal R, Gupta SK, Sood N, Rampal A, Karkara S, Kaur J. Clinical and histopathological spectrum of lichen planus. Journal of Pakistan Association of Dermatologists. 2018 Dec 13;28(3):344-50.

How to Cite This Article

Greeshma SS, Amma CRKK, Raveena R. Efficacy of *Natrum muriaticum* 1m potency in the treatment of lichen planus: A case report. International Journal of Homoeopathic Sciences. 2023;7(3):373-375.

Creative Commons (CC) License

This is an open access journal, and articles are distributed under the terms of the Creative Commons Attribution-Non Commercial-Share Alike 4.0 International (CC BY-NC-SA 4.0) License, which allows others to remix, tweak, and build upon the work non-commercially, as long as appropriate credit is given and the new creations are licensed under the identical terms.