



International Journal of Homoeopathic Sciences

E-ISSN: 2616-4493

P-ISSN: 2616-4485

www.homoeopathicjournal.com

IJHS 2022; 6(4): 609-611

Received: 15-11-2022

Accepted: 20-12-2022

Dr. Tummala Aarathi Reddy
Assistant Professor,
Department of Obstetrics and
Gynaecology, MNR
Homoeopathic Medical College
and Hospital, Telangana,
India

Dr. Sreevidhya JS
HOD and Associate Professor,
Department of Obstetrics and
Gynaecology, MNR
Homoeopathic Medical College
and Hospital, Telangana,
India

Dr. E Siva Rami Reddy
Professor and Head,
Department of Practice of
Medicine, MNR Homoeopathic
Medical College and Hospital,
Telangana, India

Corresponding Author:
Dr. E Siva Rami Reddy
Professor and Head,
Department of Practice of
Medicine, MNR Homoeopathic
Medical College and Hospital,
Telangana, India

Beauty of pulsatilla in treating style of petulant lady: A case report

Dr. Tummala Aarathi Reddy, Dr. Sreevidhya JS and Dr. E Siva Rami Reddy

DOI: <https://doi.org/10.33545/26164485.2022.v6.i4i.719>

Abstract

Stye is a painful acute infectious condition. This is also called as Hordeolum. It's an inflamed oil gland either on the upper eyelid or lower eyelid. A 22years old female presented with complaint of an internal Stye and had been treated with Pulsatilla 200, based on the totality of symptoms with follow-up of 3months.this is an evidenced based study that homoeopathy when choosen with symptom similarity gives wonderful results.

Keywords: Pulsatilla, stye, homoeopathy

Introduction

Stye is the most common complaint. It is acute inflammation of follicle over the eyelashes including the glands. This usually appears in people who strain due to refractive errors. This is an acute suppurative inflammation of the follicle of the eyelash including the glands of Zies. In the early phase the glands become red, swollen, hard and painful and usually the whole edge of the lid is oedematous, even resulting in abscess formation, which generally points near the base of one of the cilia. Recurrent styes are usually seen in Diabetics, Chronic blepharitis, initially it starts with red, swollen, hard and painful condition noted at the edge of the lid. It gives an Oedematous appearance. This may gradually progress into cilia.

Case Report

A 22years old female presented with the complaint of internal stye in the It eye to OPD on 4th June 2022. Swelling of the eye lids with mild pain. She is having discomfortness in the eye. Stye is like a pimply appearance.

History of presenting complaint

Complaints started since week days, but due to discomfortness unable to study. History of prone towards recurrent styes. She is having chronic exposure towards mobile in view of her studies. Excessive strain of eyes due to her exams and lack of sleep. Itching in the eyes. Stye is like pimple in appearance. She is mild girl with weeps easily. Highly emotional. Can't tolerate heat. Due to hot weather feels very much uncomfortable.

Generals

Appetite: Regular
Bladder: Normal
Thirst: Normal
Stool: Regular
Sleep: Disturbed
Sweat: Normal

Mental Generals

Emotional
Weeping tendency
Mild
Likes to be sympathatised

Evaluation of Symptoms

- Timid
- Weeps easily
- Emotional
- Excessive straining of eyes
- Itching in eyes
- Discomfortness with pimple like appearance of styes

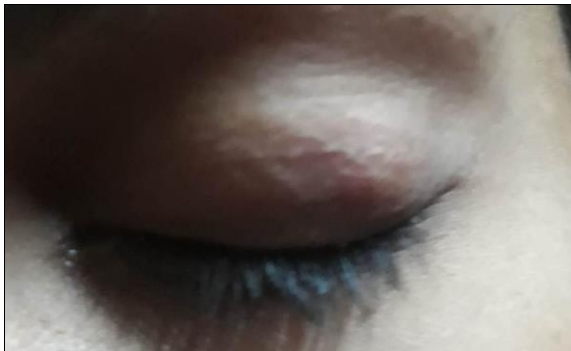

Fig 1: (4th June 2022)

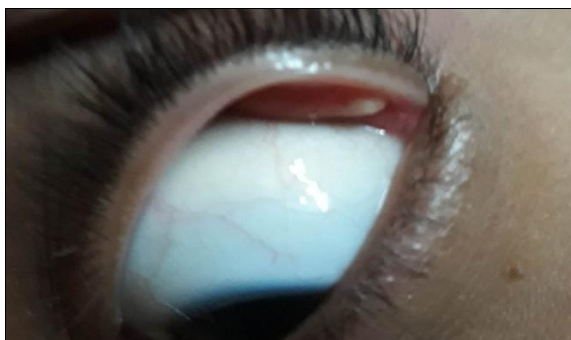

Fig 2: (4th June 2022)

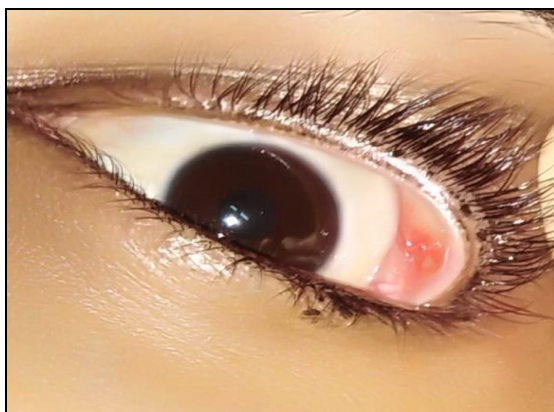

Fig 3: (7th June 2022)

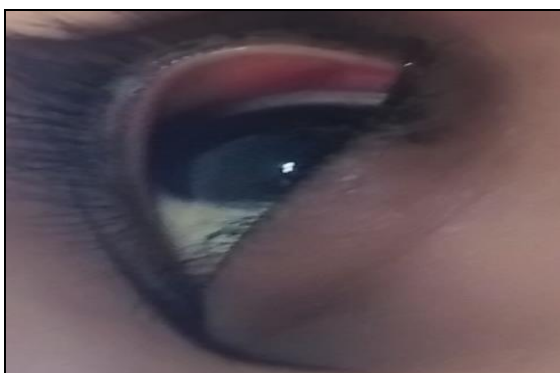


Fig 4: (9th June 2022)

Remedy Name	Puls	Sep	Sulph	Carbn-s	Aur
Totality / Symptom Covered	11 / 4	11 / 4	11 / 4	10 / 4	9 / 4
[Kent] [Mind]Timidity: (78)	2	3	3	2	2
[Kent] [Mind]Weeping,tearful mood,etc.: (166)	3	3	3	3	2
[Kent] [Mind]Excitement,excitable: (163)	3	2	2	2	3
[Kent] [Eye]Styes: (37)	3	3	3	3	2

Fig 5: Repertorisation Chart

Therapeutic Intervention

Case taking was done and repertorisation is done by following kentian method of Repertorisation, Pulsatilla 200 was selected based on the consideration of mental symptoms and also on the basis of pimple like stye. Patient is asked to report after 3days.

Table 1: Data of symptoms, follow up, Prescription

Date	Symptoms	Prescription/Dose	Justification
4 th June 2022(1 st visit)	Swelling over the upper eyelid, pimple like stye seen	Pulsatilla 200/1dose	-----
7 th June 2022(2 nd visit)	Swelling slightly decreased leaving redness	Placebo/1 dose	Improving
9 th June 2022 3 rd visit	Swelling decreased, no pimple like appearance of stye noted.	Placebo/1 dose	Improving
12 th June 2022 4 th visit	Swelling completely resolved on the upper eyelid	Placebo/1 dose	Resolved completely



Fig 6: (12th June 2022)

Conclusion

This is a case of stye, Based on the symptom similarity, individualization & Repertorisation Pulsatilla 00 was selected, with single dose of 200 potency Pt was resolved with the complaint of stye. Thus Homoeopathy proves it not only treats symptoms, It is treated from the roots.

Financial support and sponsorship: Nil.

Conflicts of interest: None declared.

References

1. BM Chatterjees Handbook of ophthalmology, 6th edition revised by L.P Agarwal. CBS Publishers & Distributors PVT. LTD, New Delhi; c1997. p. 260.
2. William Boericke, New Manual of Homoeopathic. Materia Medica & Repertory, Augmented Edition. Indian books & periodicals publishers New Delhi; c2015 Dec.
3. Parsons Diseases of the Eye, Ramanjit Sihota, Radhika Tandon, 22nd Edition, Reed Elsevier India Private Limited; c2015. p. 452.
4. JT Kent Repertory of the Homoeopathic Materia Medica 6th American edition Indian books and Periodical publishers.
5. Allen HC. Keynotes Rearranged & Classified with leading remedies of Materia medica added with other leading nosodes & bowel nosodes 10th edition Indian books & Periodicals publishers.
6. Khurana AK. Comprehensive Ophthalmology, 7th edition, Jaypee brothers medical publishers, New Delhi; c2019. p. 383.
7. Khurana AK. Review of Ophthalmology, Seventh Edition, Jaypee brothers medical publishers, New Delhi; c2019. p. 131.
8. Hahnemann S, Boericke W, Krauss J. Organon of Medicine. 6th ed. New Delhi: B. Jain Publishers (Pvt.) Ltd.; c2003.

How to Cite This Article

Reddy TA, Sreevidhya JS, Reddy ESR. Beauty of pulsatilla in treating style of petulant lady: A case report. International Journal of Homoeopathic Sciences. 2022;6(4):609-611.

Creative Commons (CC) License

This is an open access journal, and articles are distributed under the terms of the Creative Commons Attribution-NonCommercial-ShareAlike 4.0 International (CC BY-NC-SA 4.0) License, which allows others to remix, tweak, and build upon the work non-commercially, as long as appropriate credit is given and the new creations are licensed under the identical terms.