



International Journal of Homoeopathic Sciences

E-ISSN: 2616-4493

P-ISSN: 2616-4485

www.homoeopathicjournal.com

IJHS 2022; 6(1): 04-06

Received: 20-10-2021

Accepted: 05-12-2021

Dr. Tummala Aarathi Reddy
Assistant Professor,
Department of Obstetrics and
Gynaecology, Kaloji Narayana
University, Sangareddy,
Telanagana, India

Fascination of leopards bane in treating bruised injury: A case report

Dr. Tummala Aarathi Reddy

DOI: <https://doi.org/10.33545/26164485.2022.v6.i1a.507>

Abstract

Leopard bane is a fascinating remedy in treating bruised injuries. This alpine remedy usually promotes fast recovery from trauma, swelling. This remedy is also indicated in Postoperative care. A case of 5years old boy had a bruised injury over right upper eyelid was treated with Arnica. Its an evidence based case report that Arnica works wonders in treating Bruised injuries.

Keywords: Injury, arnica, homoeopathy, bruised

Introduction

As we know homoeopathy is based on law of similars according to our Father of Homoeopathy symptoms caused by a substance in healthy individual can be treated by the same remedy which produce the symptoms. Leopard's bane is a remedy suggested by various Homoeopathic physicians for treating injuries, to control bruising, reduce swelling & helps in promoting health. There are many medicines in Homoeopathic Repertory ^[1, 5] & Materia medica ^[2, 3] for treating bruised injuries. In homeopathy as we follow holistic approach cure is obtained from body and mind according to Hahnemann's Law of similar ^[4].

The alpine plant Arnica Montana is recommended by homeopathic practitioners for treating injuries on account of its alleged ability to control bruising, reduce swelling and promote recovery ^[6]. Homeopathic arnica is popular with patients undergoing surgery, who hope it will reduce postoperative complications. However, despite favorable anecdotal reports ^[7].

Case Report

A five year old boy had reported to the clinic on 23rd April 2021 with the complaints of injury over the right upper eyelid. The child developed bluish discoloration followed by swelling and was crying due to pain and discomfortness in the closure of eye. Pain aggravated by closing the eye, ameliorated by moving the eyelid.

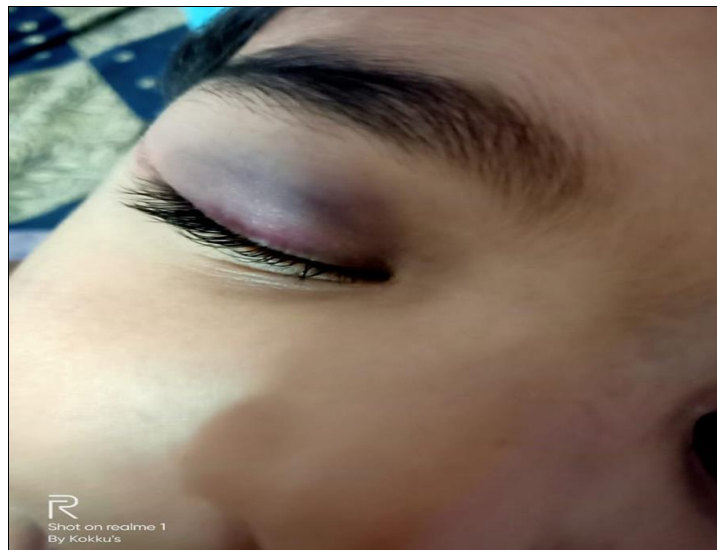

Fig 1: Injury before treatment

Corresponding Author:
Dr. Tummala Aarathi Reddy
Assistant Professor,
Department of Obstetrics and
Gynaecology, Kaloji Narayana
University, Sangareddy,
Telanagana, India

Patient Information

A 5yrs old boy had a hit with the corner edge of a table to rt eye while playing. Followed by which the child started crying due to pain and unable to open the eyelid as there is severe pain. Child was irritable & is frightened due to fall. Child doesn't want the mother to touch or either see the wound due to severe pain [8].

Clinical findings

When the child was examined found bluish discoloration over the Right upper eyelid, pain in Right eye, difficulty in closing the eye, swelling, and redness.

Arnica was selected as the child had bruised injury which was aggravated by 2nd closure of eye lid. According to homoeopathic physicians Leopards bane is the prior most remedy to be chosen even if injury is received years ago [3]. Injury is a word which is analogous with the usefulness of Leopards bane in treating bruised injury [7]. On the basis of above mentioned case, one dose of Arnica 200 twice a day was administered.

The patient was instructed not to use any other treatment for the same condition.

Evaluation of Symptoms

- Child is irritable & frightened
- Child s sensitive to be touched
- Chilly Pt.
- Bluish discoloration of Right upper eyelid after blunt injury
- Swelling over the Right upper eyelid.

Repertory analysis was done with the Kent’s Repertory using Zomoeco software by Homeopath [9].

Timeline

Patient visited OPD on 23rd April 2021. Medicine was prescribed on same day. Patient had regular follow ups .Medicine was repeated on 25th April 2021. Placebo was given at 3rd,4th&5th visits

Therapeutic Intervention

Case report was collected in an according manner and repertorisation as done by using Kents method Arnica montana 200 was selected. The patient was asked to report after 6days.

improvement in discoloration of bruised injury. The patient then returned on 25th April 2021 with further improvement with decrease in bluish discoloration and slight reduction in swelling. On third day, There was further improvement observed in which complete discoloration decreased, reduction in swelling, and watering of eyes had decreased. On fourth day, There was further more progress in improvement & on 5th day observed there is complete recovery of bruising of Right upper eyelid.



Fig 3: 1st day after treatment

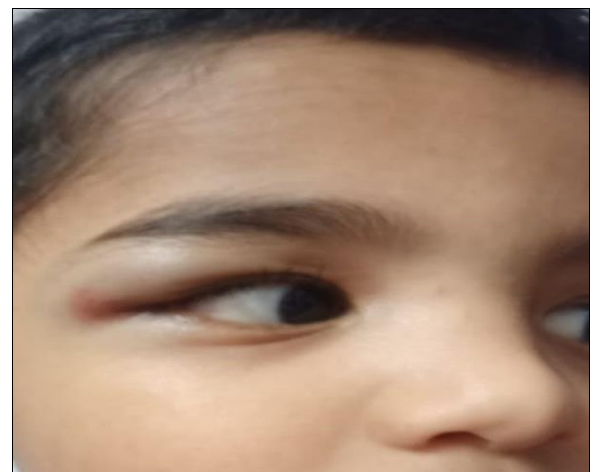


Fig 4: 2nd day after treatment



Fig 5: 3rd day after treatment

Repertorisation					
Symptoms: 3 Remedies: 247 Applied Filter					
Remedy Name	Acon	Arn	Sil	Ant-c	Cham
Totally / Symptom Covered	6 / 3	6 / 3	6 / 3	6 / 2	6 / 2
[Kent] [Mind]Irritability (see anger): (245)	3	2	3	3	3
[Kent] [Eye]Injuries,from: (12)	1	2	1		
[Kent] [Mind]Touched,aversion to being: (33)	2	2	2	3	3

Fig 2: Reptorial Analysis [9]

During follow up every change was noted(Figures 3-6)Medicine was not repeated as long as improvement continued.

Follow up

The patient first followed up on 24th April 2021 with

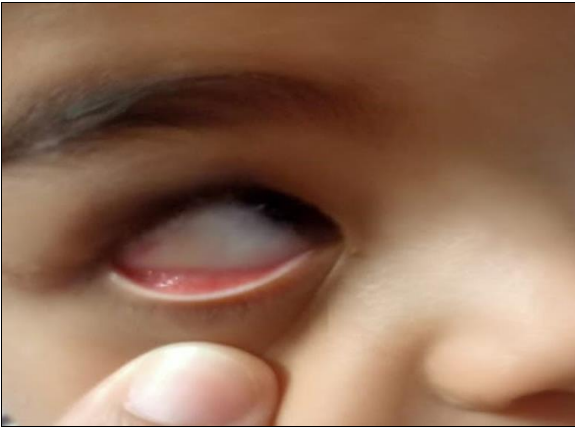

Fig 6: 4th day after treatment

Discussion and conclusion

This case report suggests the efficacy of homoeopathic remedy in case of blunt injury. No local application was used. On the basis of Patients mother symptoms and in reference to Materia medica. Arnica was selected and as Arnica having great affinity in treating injuries, hence it had once again proved its efficacy.

Declaration of Patient Consent

As the Patient is minor consent of parents had been obtained.

References

1. Kent J. of the Homoeopathic Materia Medica 6th edition. New Delhi: B. Jain Publishers Private Ltd. 2013.
2. Boericke W, Boericke O. Pocket Manual of Homoeopathic Materia Medica Comprising of the characteristics and Guiding Symptoms of all Remedies (Clinical and Pathogenetic)
3. HC Allen MD. Keynotes Rearranged & Classified with leading remedies of the Materia edica added with other leading Nosodes & Bowel Nosodes 13th edition. New Delhi Indian Books &Periodical Publishers.
4. Hahnemann' S, Boericke W, Dudgeon R. Organon of Medicine New Delhi B. Jain publishers Private Ltd. 2011.
5. Schroyens F. Synthesis Repertorium Homoeopathic Syntheticum. New Delhi: B Jain Publishers Private Ltd. 2008.
6. Livingston R. Homeopathy: Evergreen Medicine. Poole: Asher Press, 1991.
7. Thomas Emlyn. Homeopathy for Sports, Exercise and Dance. Beaconsfield: Beaconsfield publishers Ltd, 2000
8. James Tyler Kent AMMD. Lectures on Homoeopathic Materia Medica 3rd edition New Delhi: B. Jain Publishers Private Ltd. 2011.
9. Zomoeo Homeopath. Using Kent's repertory version, Maharashtra, Mind Technologies, Private Limited. 2019.