



International Journal of Homoeopathic Sciences

E-ISSN: 2616-4493
P-ISSN: 2616-4485
www.homoeopathicjournal.com
IJHS 2024; 8(2): 395-397
Received: 10-04-2024
Accepted: 02-05-2024

Dr. Namrata Madhukar Bhople
Post Graduate Trainee,
Department of Organon of
Medicine and Homoeopathic
Philosophy, Government
Homoeopathic Medical College
and Hospital, Ayush Parisar,
Near Kaliyasot Dam, Bhopal,
Madhya Pradesh, India

Dr. Juhi Gupta
Assistant Professor and I/C,
Department of Research
Methodology and Biostatistics,
Government Homoeopathic
Medical College and Hospital,
Ayush Parisar, Near Kaliyasot
Dam, Bhopal, Madhya
Pradesh, India

Corresponding Author:
Dr. Namrata Madhukar Bhople
Post Graduate Trainee,
Department of Organon of
Medicine and Homoeopathic
Philosophy, Government
Homoeopathic Medical College
and Hospital, Ayush Parisar,
Near Kaliyasot Dam, Bhopal,
Madhya Pradesh, India

A case of external malady treated with internal individualized homoeopathic remedy

Dr. Namrata Madhukar Bhople and Dr. Juhi Gupta

DOI: <https://doi.org/10.33545/26164485.2024.v8.i2f.1162>

Abstract

Urticaria is a skin condition which presents as sudden appearance of wheals, itching and or angioedema. The wheals vary in size from few millimeters to centimeters and it can appear in any part of the body. Urticaria can be classified as acute and chronic depending upon the duration. A case report of 19-year-old female patient suffering from urticaria treated with individualized homoeopathic medicine is presented here.

Keywords: Urticaria, homoeopathy, rhus tox, external malady, internal remedy

Introduction

The term urticaria is defined as a transient eruption of circumscribed edematous and usually itchy swelling of the dermis ^[1]. Urticaria is caused by localized dermal oedema secondary to a temporary increase in capillary permeability ^[2]. If oedema involves subcutaneous or submucosal layer, the term angioedema is used. It is classified as acute or chronic depending upon the duration. Urticaria present for less than 6 weeks is considered to be acute and chronic if it continues for more than 6 weeks. ^[2].

Prevalence

- Urticaria is a common dermatological condition worldwide.
- Acute urticaria, in particular, is highly prevalent; with estimates suggesting that up to 20% of individuals will experience an episode of acute urticaria during their lifetime.
- Chronic urticaria, which lasts for more than six weeks, is less common but still significant. It affects approximately 0.1% to 0.5% of the population ^[3].

Underlying causes

- a) Autoimmune- due to antibodies that cross link the IgE receptors on mast cells.
- b) Drugs
- c) Allergens in food
- d) Physical stimuli like heat cold, pressure, sunlight
- e) Insect stings and bites

Clinical features: Raised, itchy wheals on the skin accompanied by intense itching. The wheals may vary in size ranging from a millimeter to centimeters. The wheals can appear on any part of the body and may be associated with angioedema ^[1].

Case Summary

A 19-year-old female patient presented in the OPD with complaints of raised urticarial rashes on shoulder hand and legs with itching and burning sensation and swelling of feet and palms for 1 day.

On interrogation she told that on previous night she travelled from bike and she had exposure to cold air. On next morning she developed these itchy raised eruptions.

Physical generals

- Appetite- decreased
- Thirst- for small quantity of water
- Tongue-moist, indented tongue

- Desire -milk
- Thermal Reaction- chilly patient

Mental Generals: Extremely restless -because of itching she was constantly changing her position and was not ready to sit at one place.

Family history: Nothing significant

Repertorization: Kent repertory

Basis of prescription: Rhus toxicodendron was prescribed on the basis of repertorial totality and after discuss with materia medica.

Discussion

A 19-year-old female patient presented in opd with urticarial rashes all over the body and swelling of palms and soles. After proper case taking totality was formed. Kent repertory was used in this case. Rhus tox was prescribed on the basis of repertorial totality and after referring to materia medica.

In aphorism 189 acc.to Dr. Hahnemann no external malady can arise, persist or even grow gross without some internal cause for example no eruption on the lip, no whitlow can occur without previous and simultaneous internal ill health and according to aphorism 190 to annihilate and cure a local malady internal remedy should be given. In aphorism 194 he mentioned that it is not useful to apply any external remedy in cases of acute local disease of recent origin or in local affection that have existed a long time ago.

Timeline and Intervention

9/12/2023 R_x Rhus Toxicodendron 30 in every 2 hours 3 doses

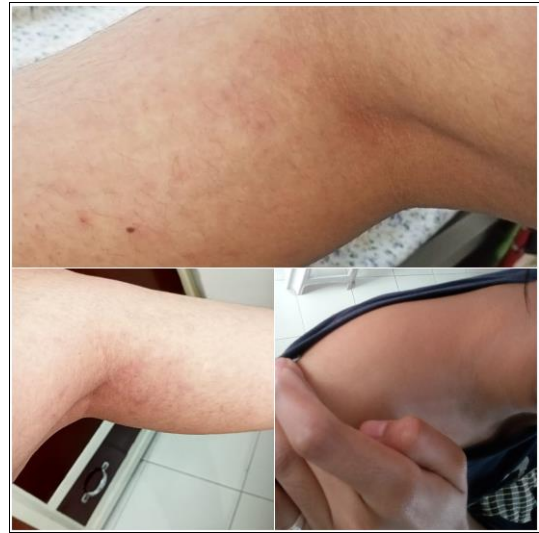

Fig 2: During Treatment- 09/10/2023 at 01:00 PM

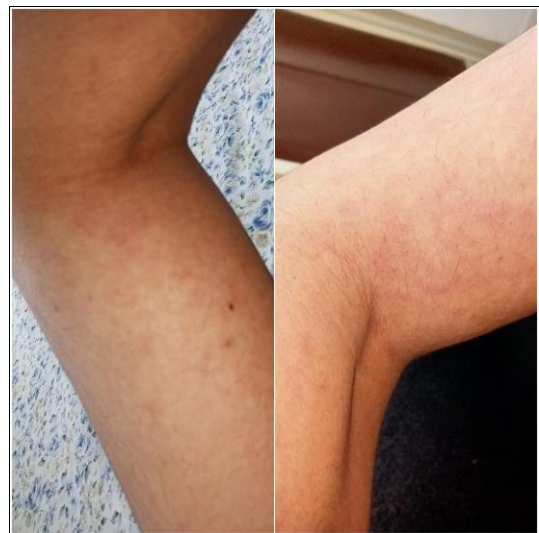

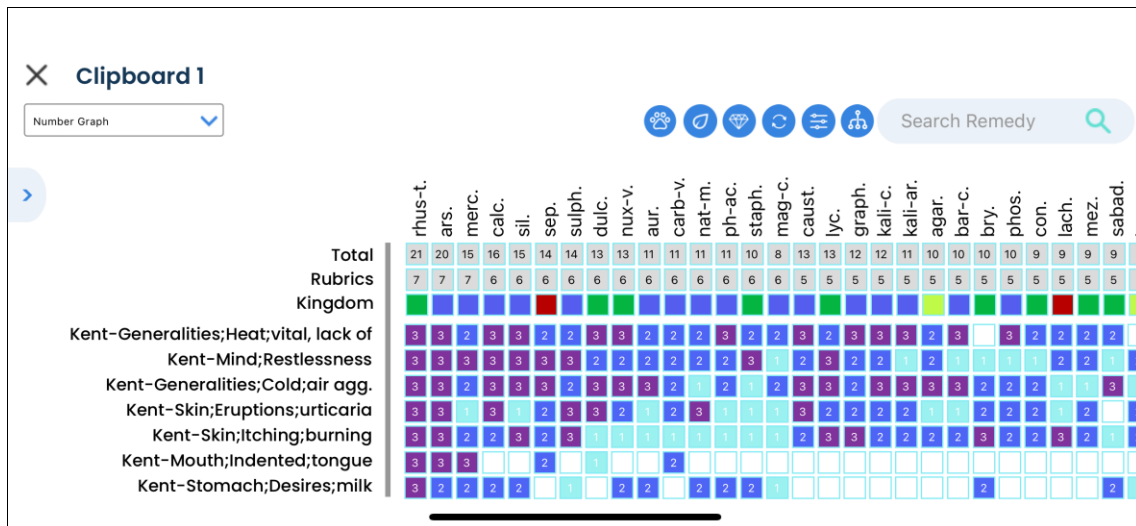
Fig 3: During Treatment- 09/10/2023 at 03:45 PM

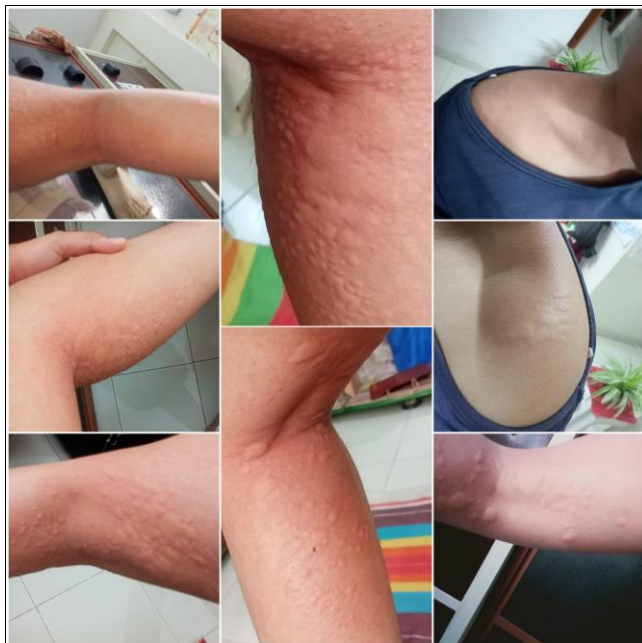

Fig 1: Before Treatment- 09/10/2023 at 10:00 AM

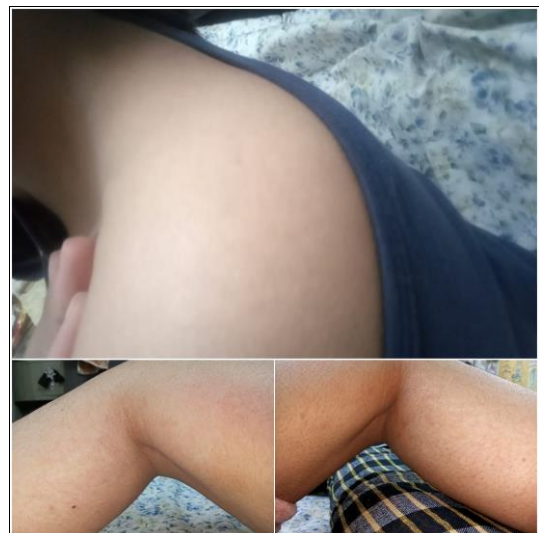

Fig 4: During Treatment- 10/10/2023 at 10:00 PM



Conclusion

Dr Hahnemann said that there are no diseases only sick people, Homoeopathy accepts holistic concept of diseases. It treats the patient as a whole and not the particular diseased part. According to him no eruption is local but it is the manifestation of internally deranged vital force. Therefore, medicine given should also act on dynamic level and it should be given internally to assist vital fore to cure

Conflict of Interest

Not available

Financial Support

Not available

References

1. Prasad PS. Urticaria. Indian J Dermatol Venereol Leprol. 2001;67:11-20.
2. Penman ID, Ralston SH, Strachan MWJ, Hobson R, editors. Davidson’s principles and practice of medicine. 24th ed. London, England: Elsevier Health Sciences; c2022.
3. https://www.ijprems.com/uploadedfiles/paper/issue_10__october_2023/32157/final/fin_ijprems1698136771.pdf
4. Hahnemann S. Organon of medicine. New Delhi, India: B Jain; c2023.
5. Boericke W. New manual of homoeopathic materia medica & repertory with relationship of remedies: Including Indian drugs, Nosodes uncommon, rare remedies, mother tinctures, relationship, sides of the body, drug Affinites & list of abbreviation: 3rd edition. New Delhi, India: B Jain; c2023.
6. Allen HC. Allen’s keynotes & characteristics: With comparisons of some of the leading remedies of the materia medica with bowel nosodes. New Delhi, India: B Jain; c2022.
7. Kent JT. Repertory of the homeopathic materia medica. New Delhi, India: B Jain; c2023.

Creative Commons (CC) License

This is an open access journal, and articles are distributed under the terms of the Creative Commons Attribution-Non-Commercial-Share-Alike 4.0 International (CC BY-NC-SA 4.0) License, which allows others to remix, tweak, and build upon the work non-commercially, as long as appropriate credit is given and the new creations are licensed under the identical terms.

How to Cite This Article

Bhople NM, Gupta J. A case of external malady treated with internal individualized homoeopathic remedy. International Journal of Homoeopathic Sciences. 2024; 8(2): 395-397.